

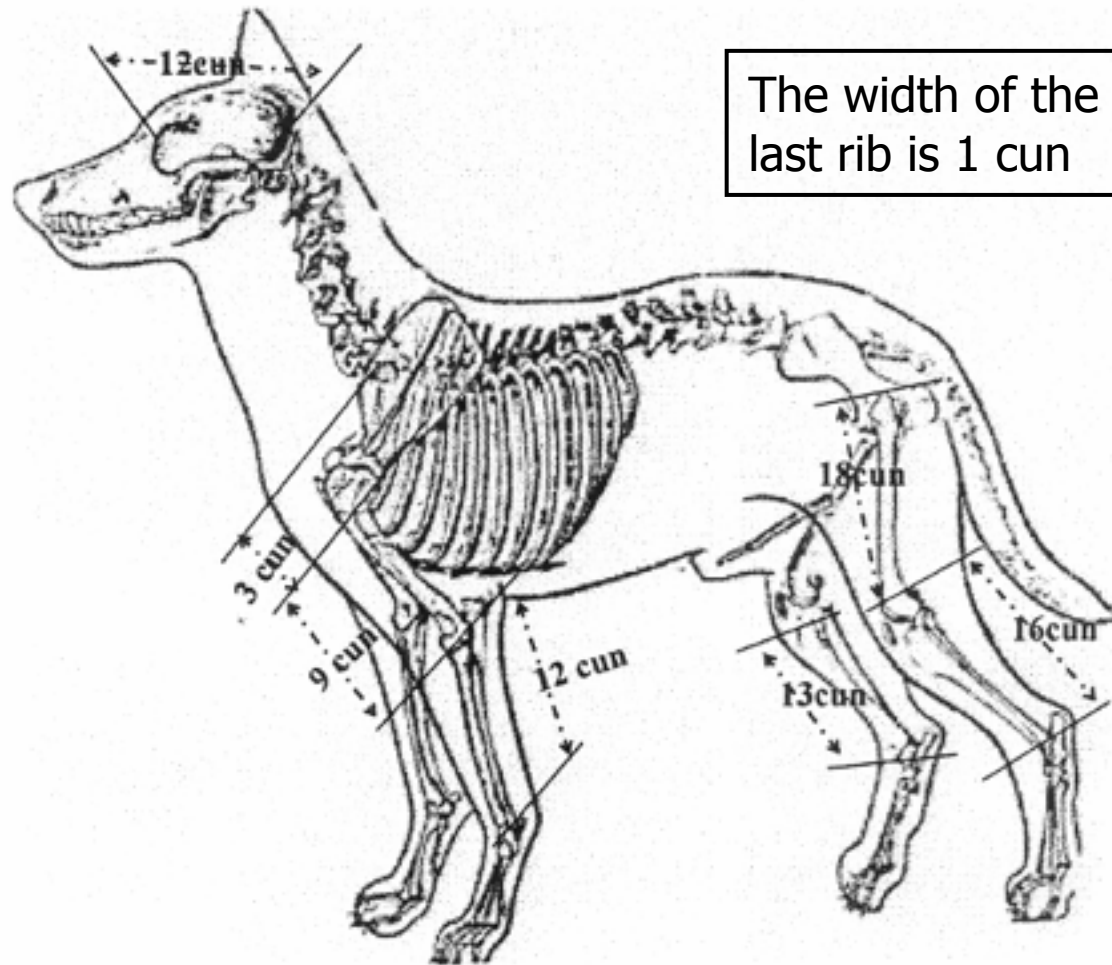
Commonly Used Canine Transpositional Acupuncture Points



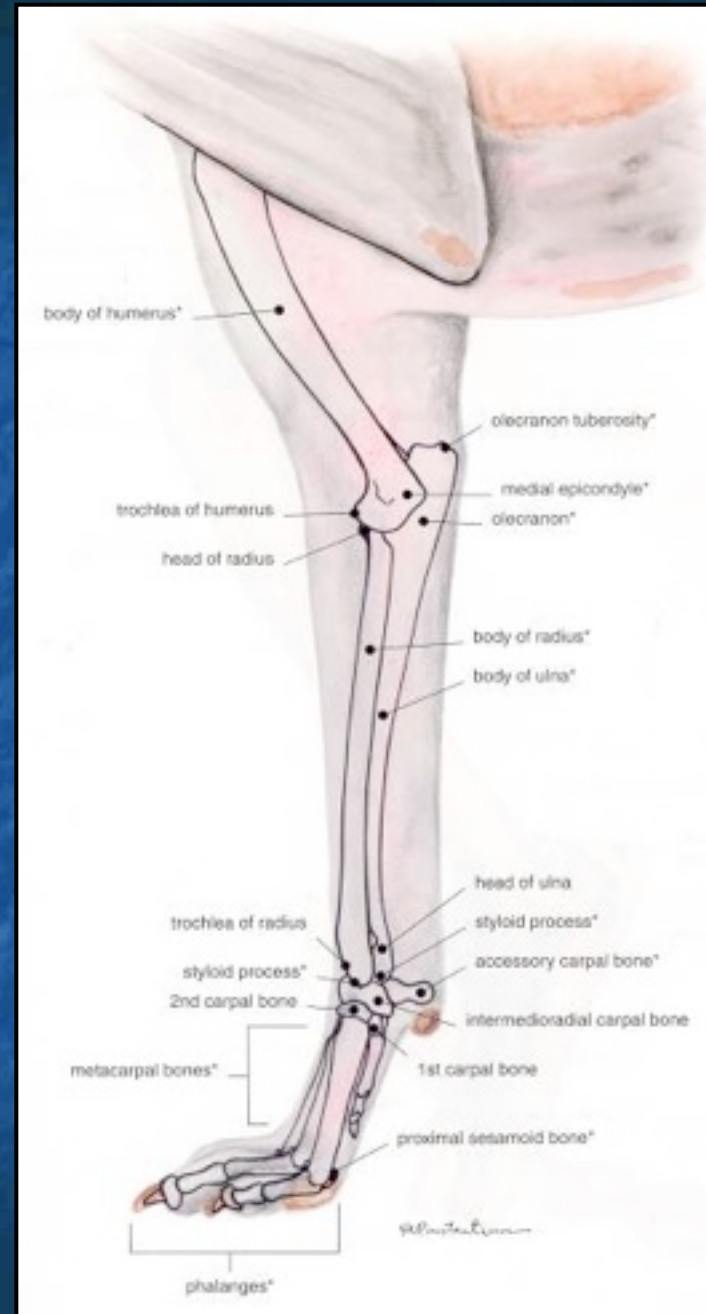Dr. Carla Leon

**Assisted by Dr. Lisa Trivisanello,
Dr. Cheryl Chrisman, Solo,
Brittany and Hurricane Frances
2004**

Chinese Inch=Cun



■ Medial Forelimb Anatomy Review



Pericardium Channel

- PC-3
- PC-6
- PC-8
- PC-9



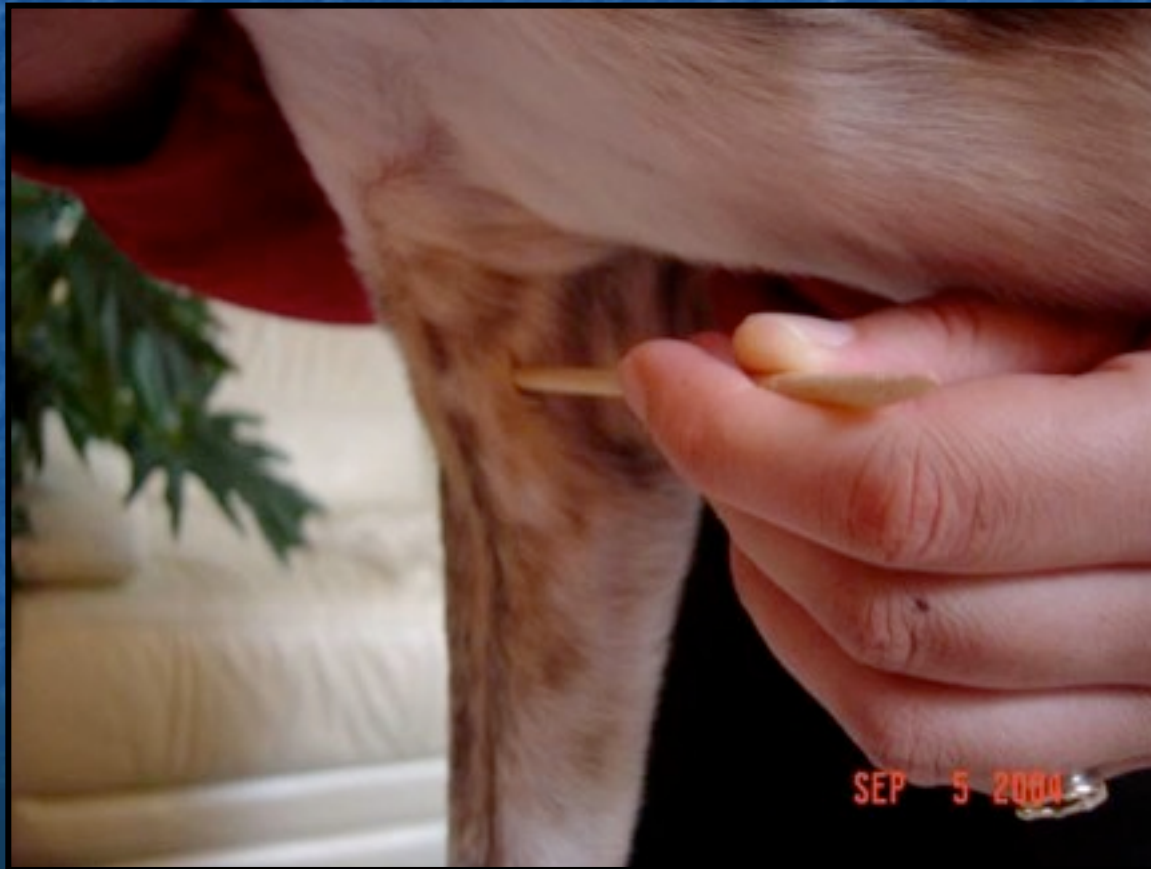- From the chest along the medial side of the forelimb to the medial front paw
- PC-1 → PC-9
- 7-9 pm
- Jue Yin

PC-3

In the crease of the elbow just medial (caudal) to the biceps tendon

He-sea pt (water)

Palpitations, vomiting, nausea, diarrhea, fever, shoulder or elbow pain



PC-6

3 cun above the transverse crease of the carpus
(Opp TH-5 on lateral side)

Luo connecting (TH-5)

Master pt for chest and cranial abdomen, anti-nausea

Confluent pt to Yin Wei



PC-8

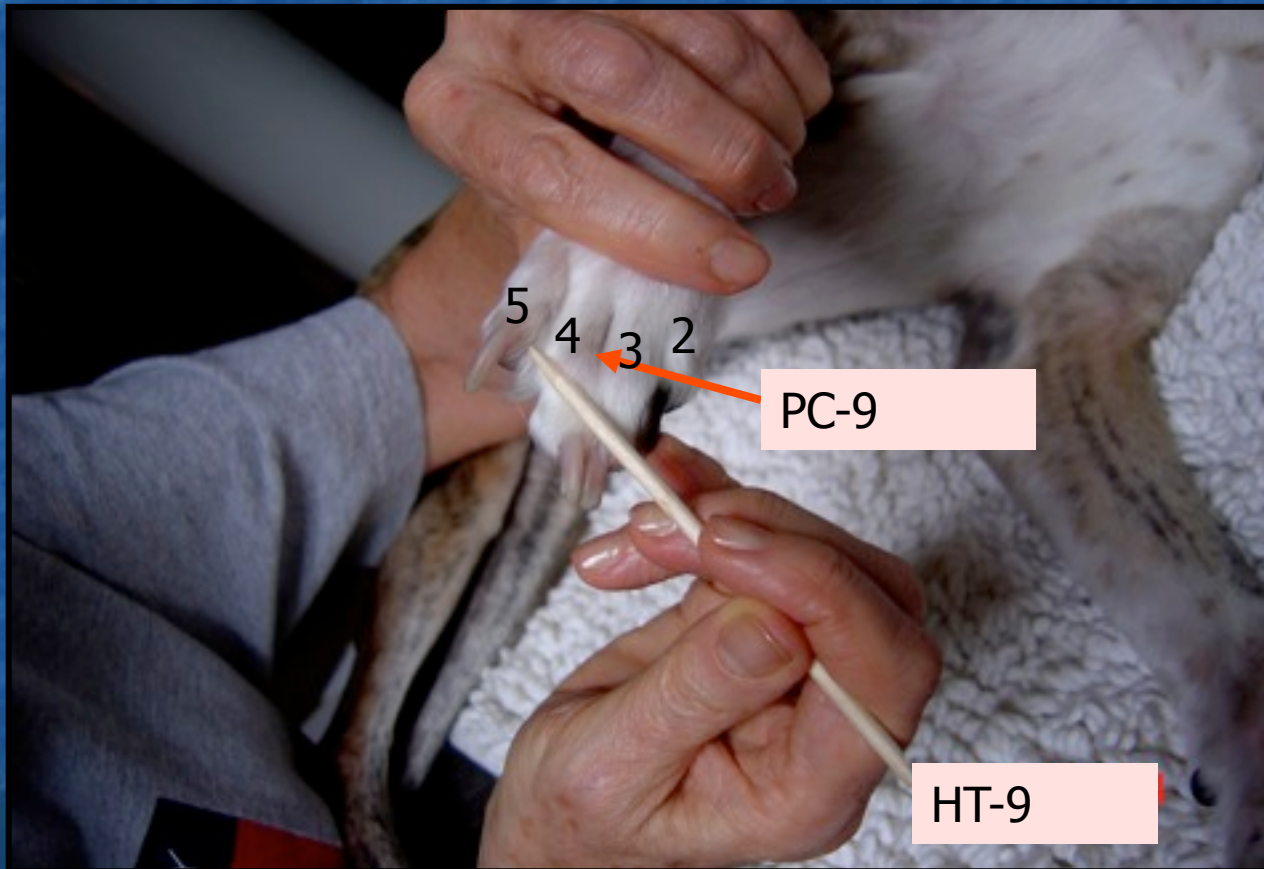
Underneath the large central pad

Ying-spring (fire)pt




PC-9

On the medial side of the 4th digit
Jing-well pt (wood), Mother pt- tonify in HT Deficiency



Triple Heater Channel

- TH-3
- TH-5
- TH-10
- TH-14
- TH-17
- TH-21
- TH-23

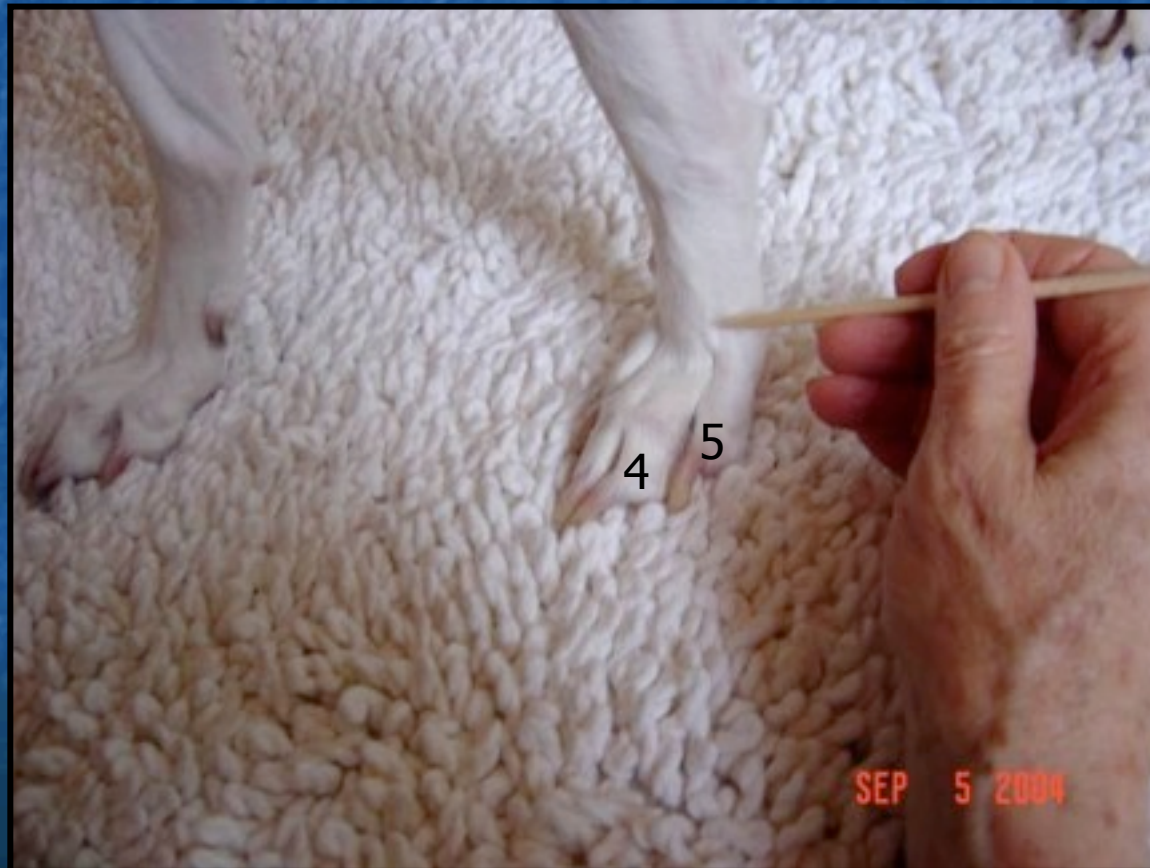

- From the front foot, along the lateral forelimb, shoulder, and neck to the ear then the eyebrow
- TH-1 → TH-23
- 9-11 pm
- Shao Yang

TH-3

Proximal to the metacarpophalangeal joint on the dorsum of the paw between the 4th and 5th metacarpals

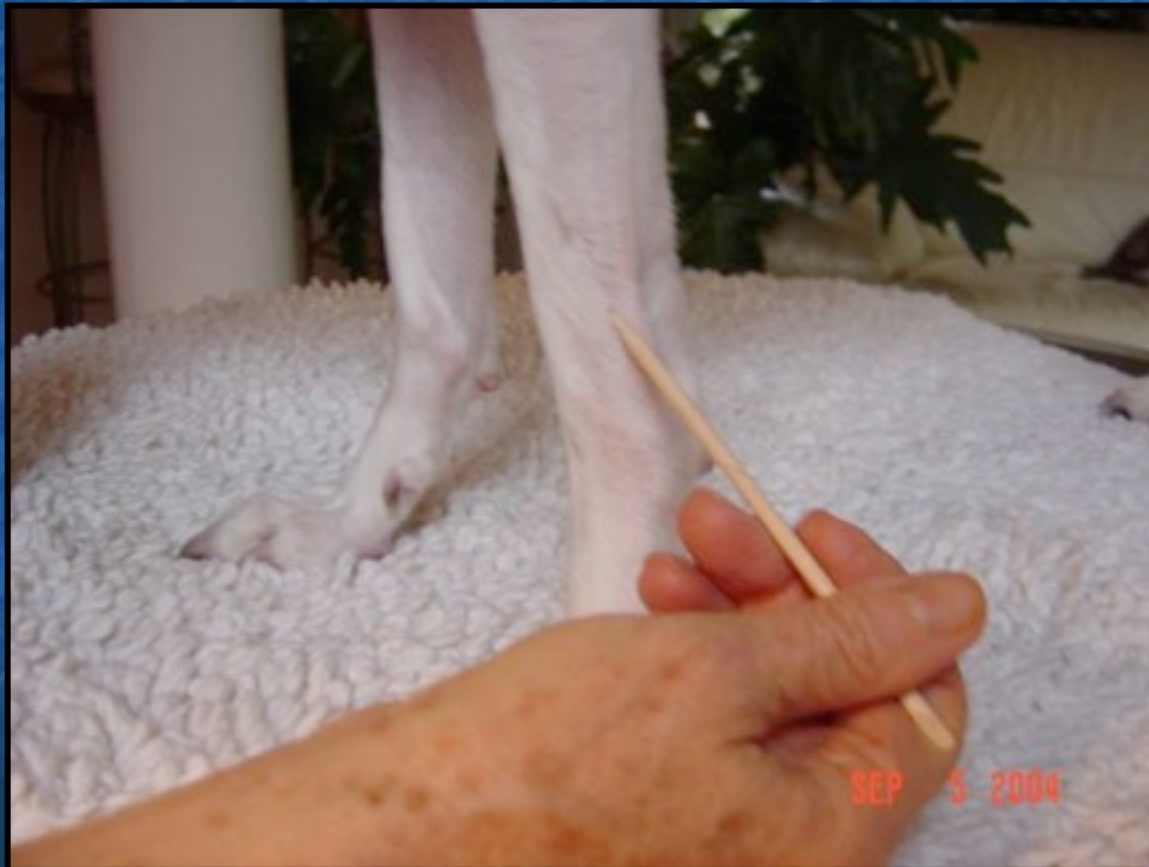Shu-stream pt (wood)



TH-5

3 cun above the carpus on the craniolateral aspect of the foreleg in the interosseous space between the radius and ulna (opposite to PC-6)

*Luo connecting (PC-6); Confluent pt to Yang-Wei meridian
Forelimb paralysis, headache, fever, red eyes, ear problems, neck*

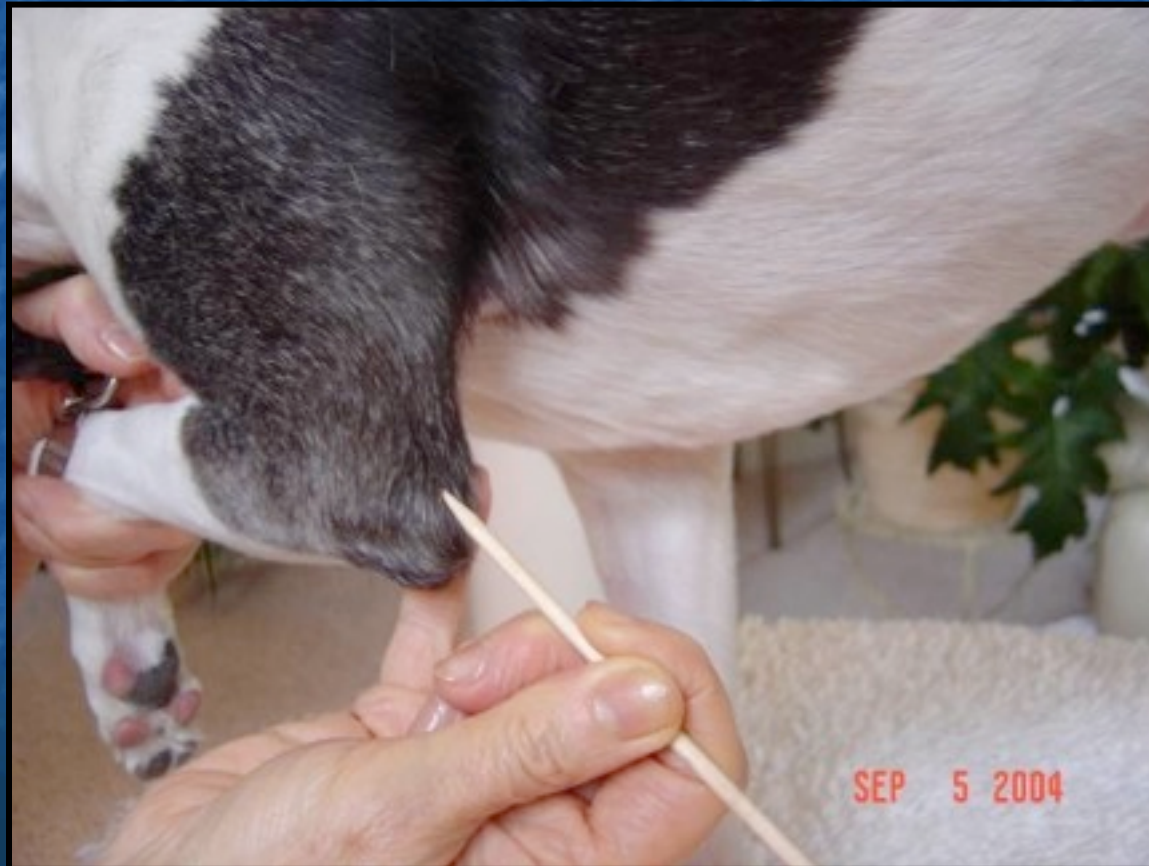


TH-10

In a depression on the triceps tendon, just proximal to the olecranon

He-Sea pt (earth), Child pt- sedate for Excess

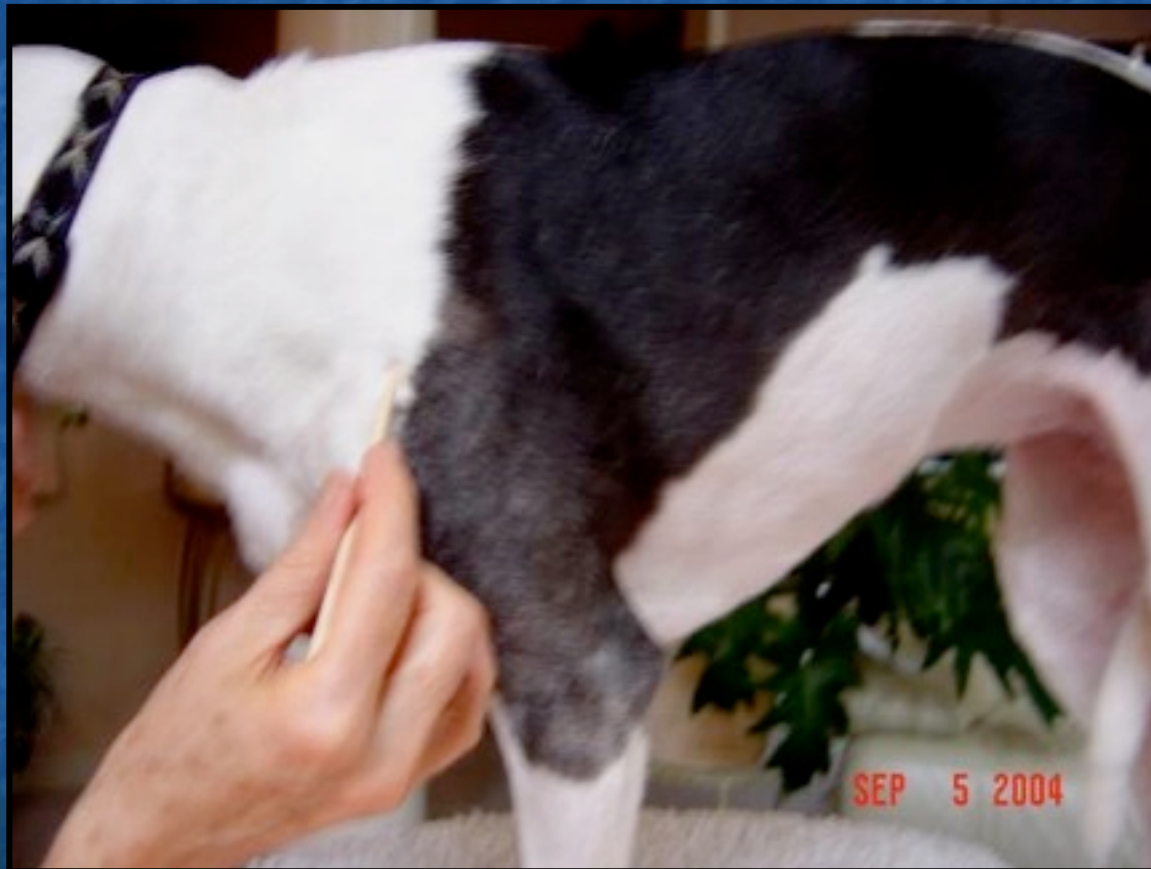Forelimb paralysis, sore throat, deafness, toothache



TH-14

Caudal and distal to the acromion on the caudal margin of the acromial head of the deltoideus muscle ("LI leads and TH trails")

Pain in the shoulder and forelimb



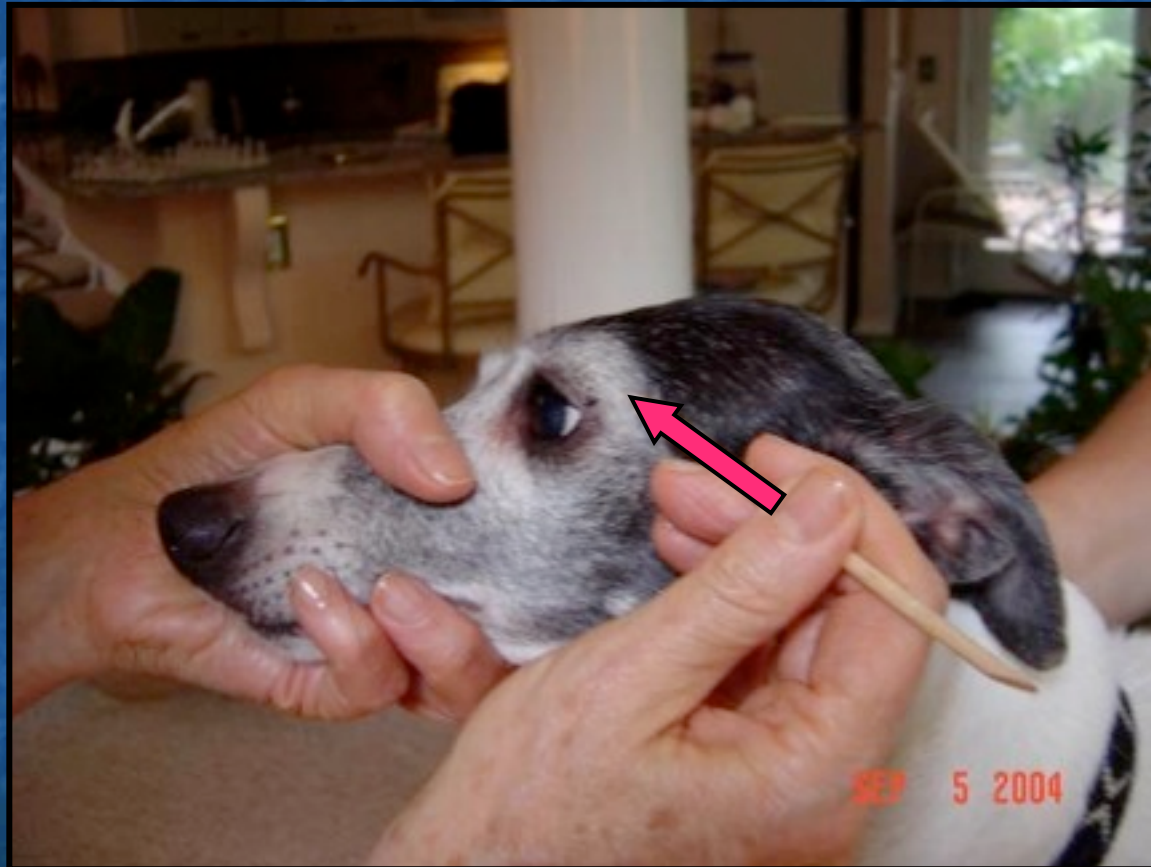TH-21

Rostral to the supratragic notch directly dorsal to SI-19, at the posterior border of the mandible and dorsal to the condyloid process when the mouth is open



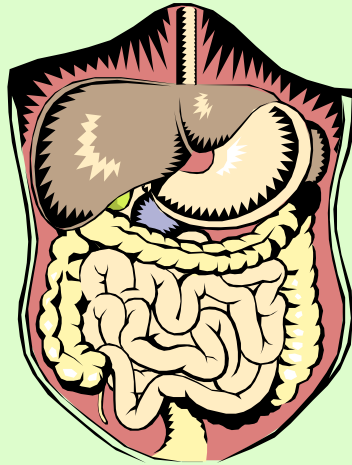
TH-23

In the depression on the rim of the orbit at the end of the eyebrow were it extended to the lateral canthus



Gallbladder Channel

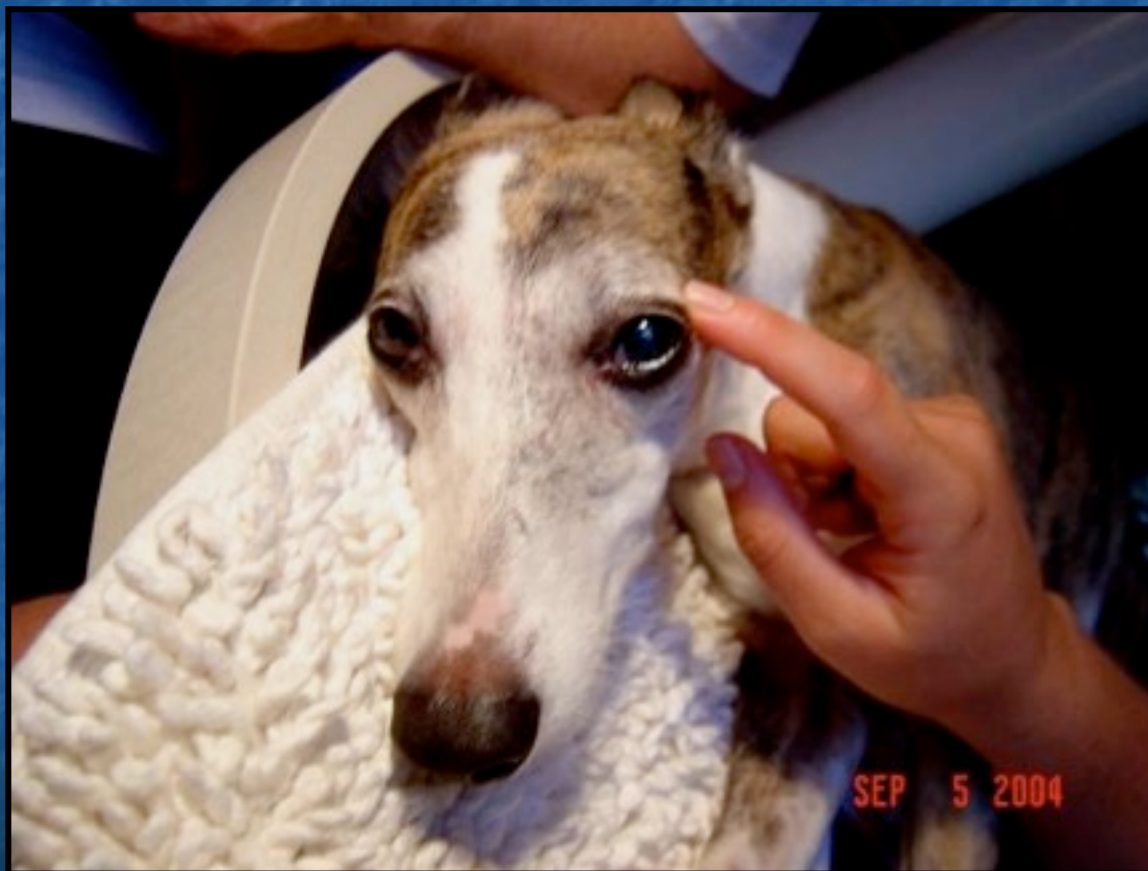- GB-1
- GB-2
- GB-14
- GB-20
- GB-21
- GB-25
- GB-29
- GB-30
- GB-31
- GB-33
- GB-34
- GB-39
- GB-41



- From the eye, around the ear and face, along the neck, lateral chest, hip, lateral hind limb to hind foot
- GB-1 → GB-44
- 11- 1 am
- Shao Yang

GB- 1

0.2 cun lateral to the lateral canthus in the depression over the rim of the orbit



GB-2

Rostral to the intertragic notch directly below SI-19 at the posterior border of the condyloid process with the mouth open

Facial paralysis, syncope, Wind pattern, Shen disturbance



GB-14

1 cun above the midpoint of the extended eyebrow (end of the visible eyebrow)

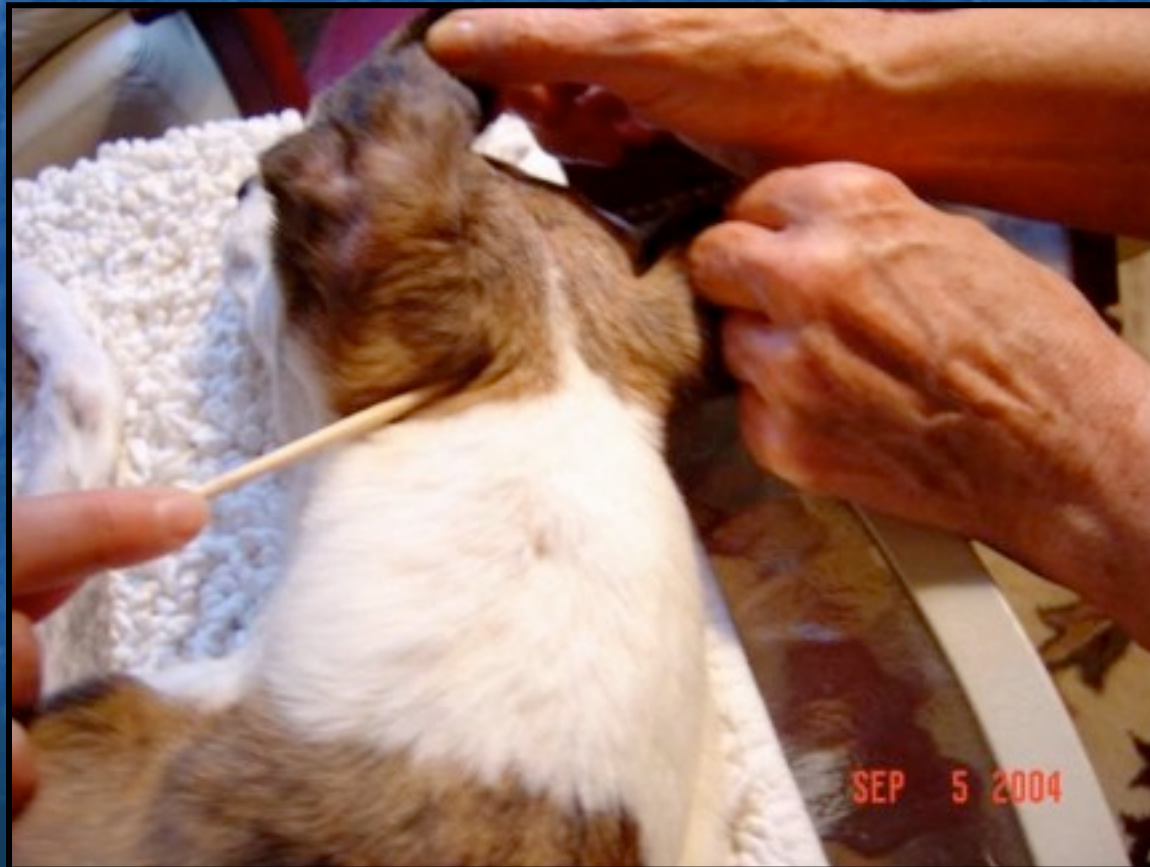Keratitis, conjunctivitis, uveitis



GB-20

Rostral and medial to the cranial edge of the wings of the atlas in a depression below the occipital bones and medial to the jugular process

External Wind, Internal Wind, epilepsy, cervical stiffness, headache,



GB-21

In a groove in the muscle in front of of the scapula midway between GV-14 (dorsal midline between C7-T1) and the acromion



GB-25

On the lateral side of the abdomen on the lower border of the free end of the 13th rib

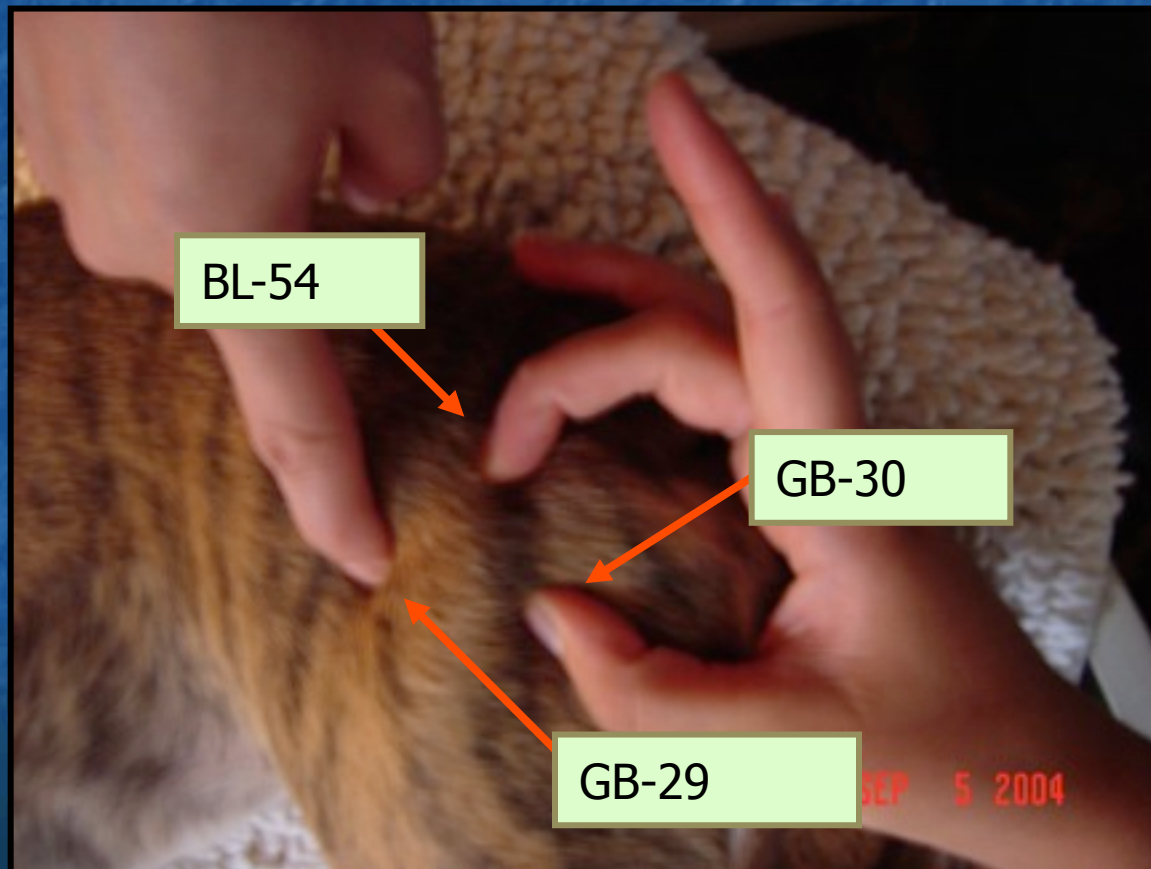
Front Mu alarm pt for KID



GB-29

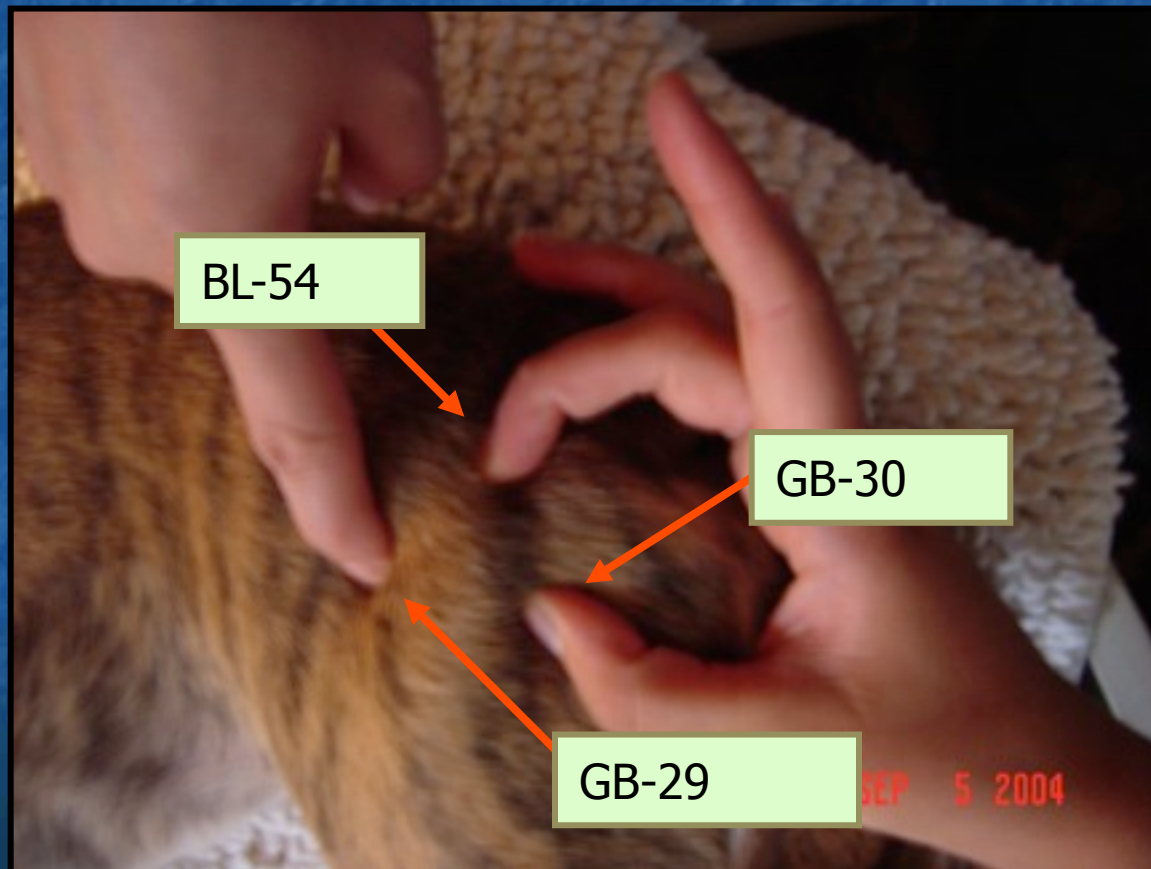
In a depression cranial to the greater trochanter (one of the 3 "bowling ball pts" around the head of the femur)

Arthritis of the coxofemoral joint, gluteal muscle pain, hind limb pain or paralysis



GB-30

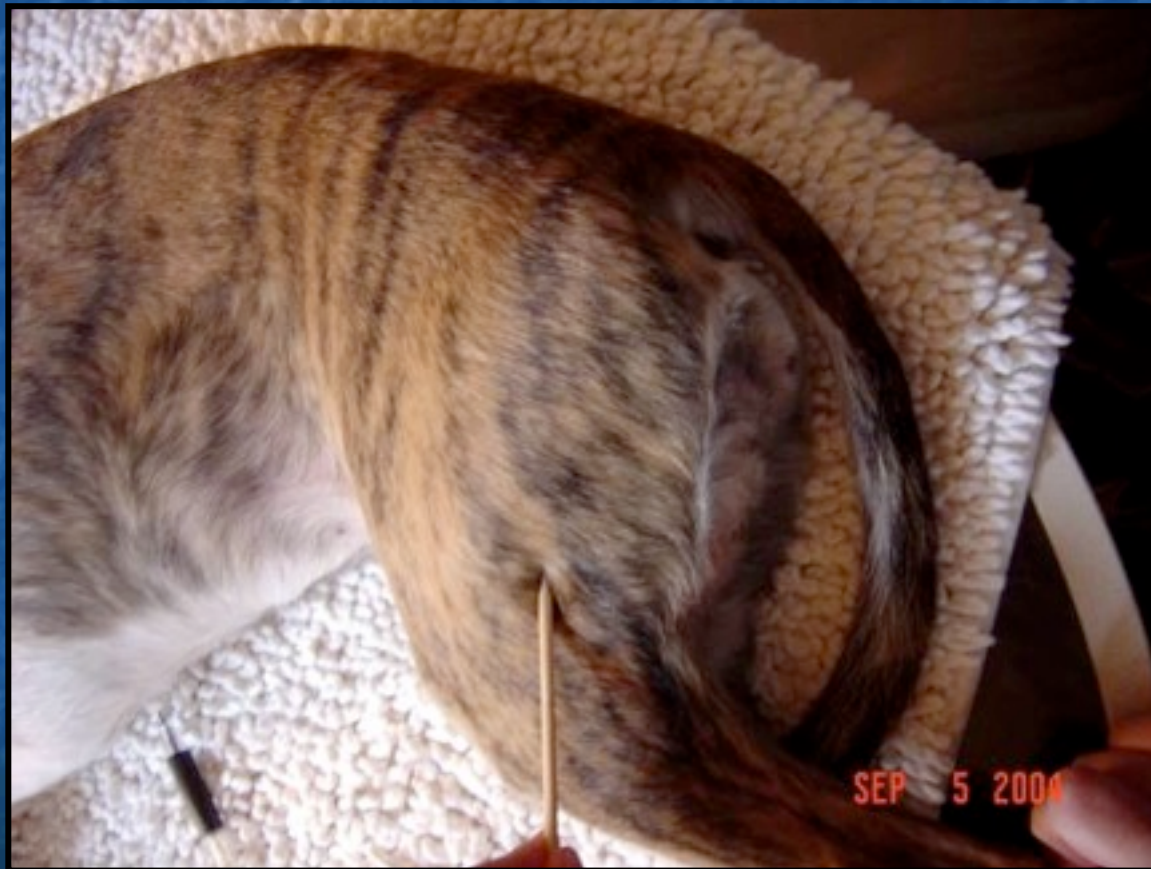In a depression midway between the greater trochanter and the tuber ischii (one of the 3 "bowling ball pts" around the head of the femur)



GB-31

In the groove between the femur and the biceps femoris muscle, 7 cm above the lateral femoral condyle

Pruritis, hind limb paralysis, sore hind foot



GB-33

In the depression between the insertion of the biceps femoris tendon and the femur in the hollow above the lateral condyle of the femur

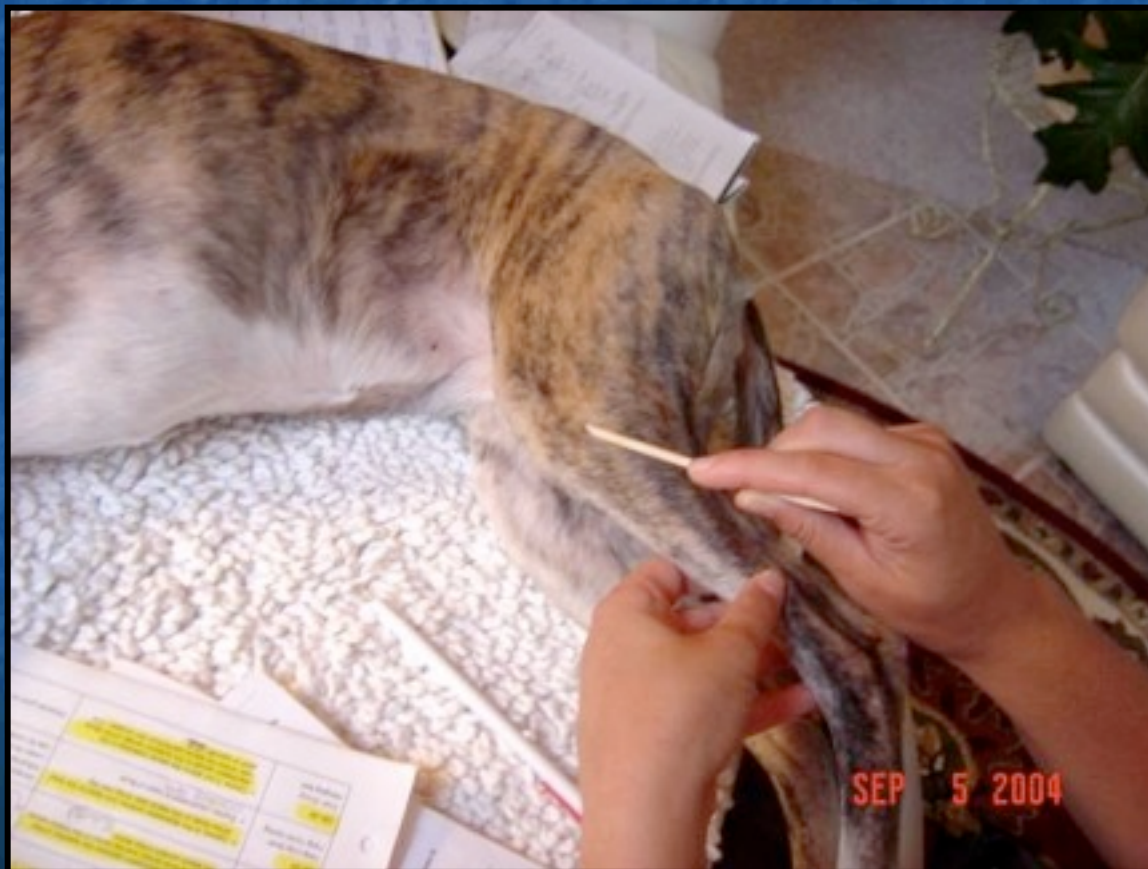Stifle problems



GB-34

In the depression anterior and distal to the head of the fibula on the lateral side of the rear leg (Opp SP-9 on medial side)


*He-Sea (earth), Lower He-Sea pt for GB,
Influential pt for ligaments & tendons*



GB-39

3 cun above the lateral malleolus in the depression caudal to the posterior border of the fibula near where the lateral saphenous vein crosses (Opposite to SP-6 on the medial side)

Influential pt for Marrow and CNS, cervical stiffness, paraplegia, anal



GB-41

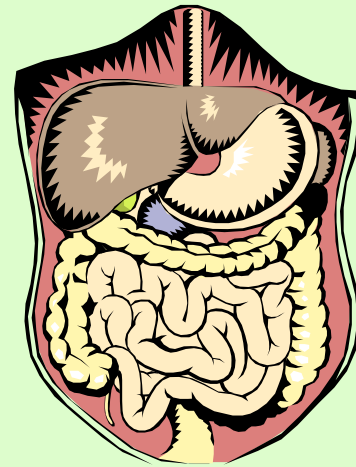
In the depression proximal to the distal junction of the 4th and 5th metatarsals

*Shu-stream pt (wood); Confluent pt to Dai meridian
Tendonitis, urinary incontinence, abnormal cycling, eye problems,
mastitis*



Liver Channel

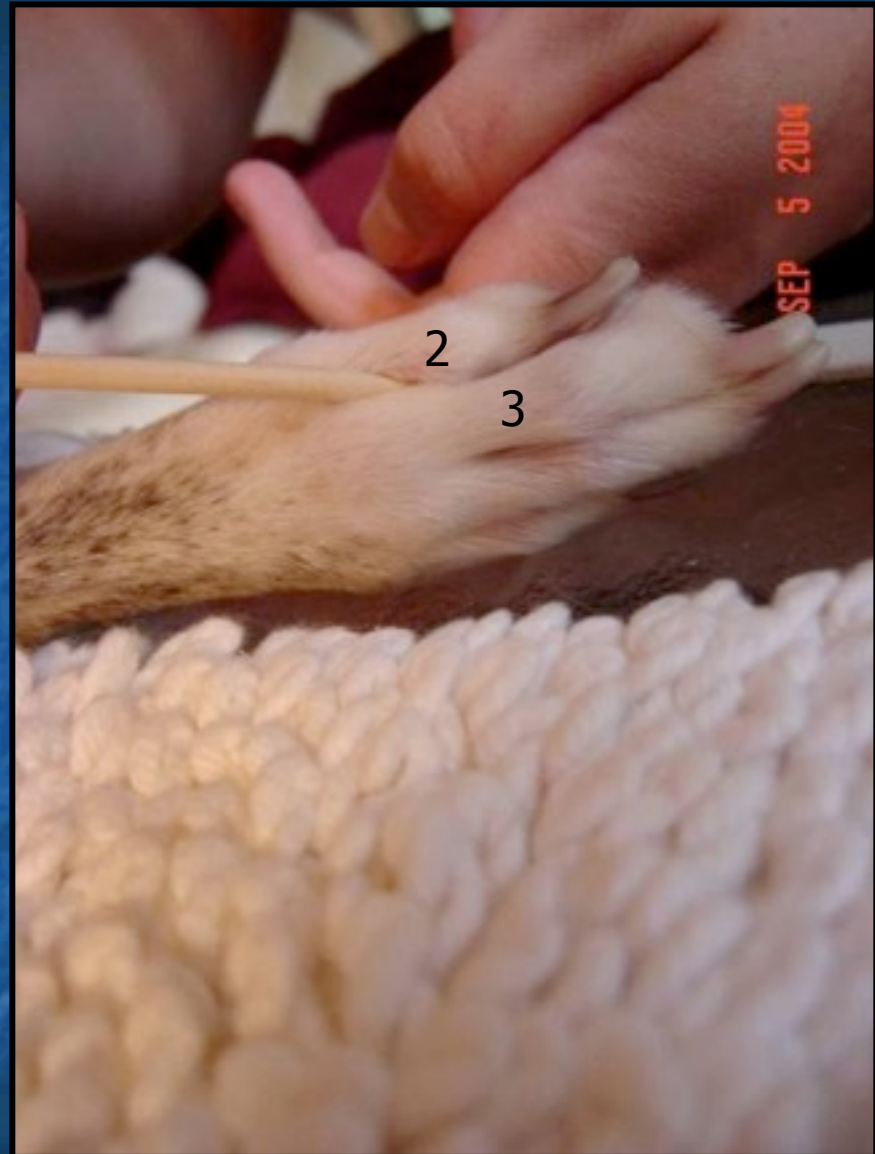- LIV-2
- LIV-3
- LIV-8
- LIV-13
- LIV-14
- From hind foot to chest
- LIV-1 → LIV-14
- 1-3 am
- Jue Yin



LIV-2

On the lateral aspect of the second toe distal to the metatarsophalangeal joint in the webbing


*Ying-spring pt (Fire)
Liver Yang Rising, eye
problems, abnormal
cycling*



LIV-3

Between the 2nd and 3rd
metatarsals proximal to the
metatarsophalangeal joint

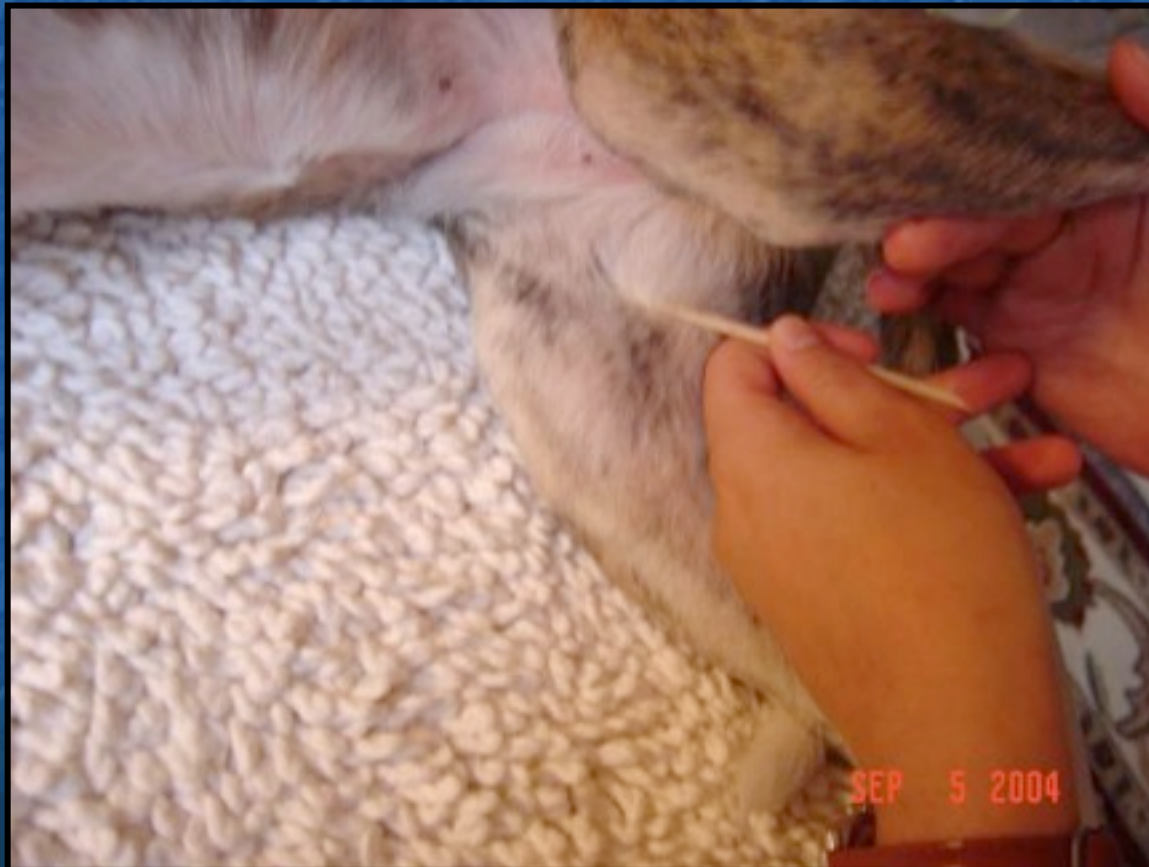Shu-stream pt (earth)
Yuan Source pt
LIV Qi stagnation
Paralysis of hind limbs



LIV-8

On the medial side of the knee, above the medial end of the popliteal crease between the medial femoral condyle and the insertion of the semimembranosus and semitendinosus m

He-Sea (water)

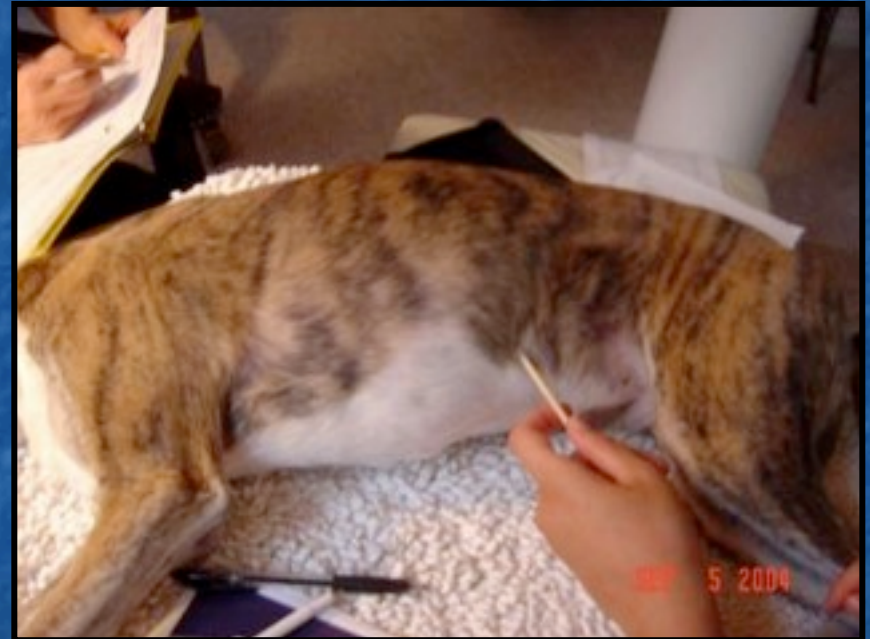
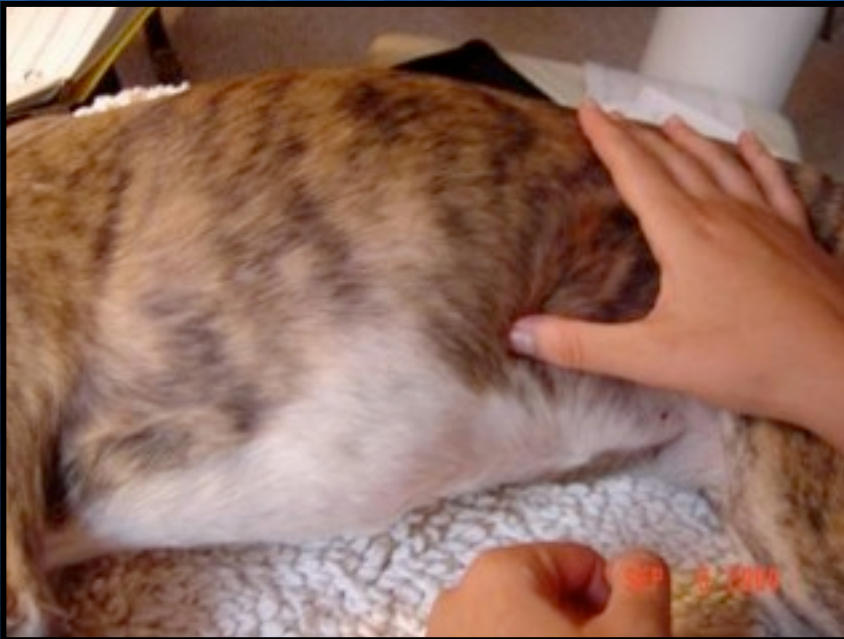
LIV-13

On the lateral side of the body just below the free end of the 12th rib

Front Mu Alarm pt for SP

Influential for Yin (Zang) organs; Master pt for viscera, colic, diarrhea, abdominal mass, muscle pain



LIV-14

In a depression at the costocondral junction near the mammary line at the 6th intercostal space

Front Mu alarm point for the Liver

Hepatic disorders, mastitis, pleuritis, chest pain, muscle pain

